138 Cryosurgery

Paola Pasquali

Key features

- A minimally invasive surgical technique that utilizes subzero temperatures to destroy benign, premalignant, and malignant lesions
- Compared to standard excisional surgery, cryosurgery requires less time to perform but healing time is often more prolonged as it occurs via second intention
- Damage to surrounding structures is predictable and can be limited, with the preserved underlying stroma providing a structural framework for wound repair
- The preferred and most commonly used cryogen is liquid nitrogen due to its very low boiling point (−196 C) which allows for freezing of skin lesions at temperatures needed for their destruction; this includes malignant cells which require freezing temperatures of at least −50 C
- Cryosurgery often leads to an excellent cosmetic result, but in patients with darker skin phototypes, hypopigmentation due to destruction of melanocytes can occur

HISTORICAL BACKGROUND

Reducing the temperature of the skin was initially done to provide anesthesia or lessen inflammation. With the advent of potent cryogens, selective destruction of tissue became possible. James M. Arnott is credited with first describing the use of controlled freezing in the 1800s to destroy tumors[1]. Liquefied oxygen and carbon monoxide preceded the introduction of liquid nitrogen (LN) by Carl von Linde. By 1898, James Dewar had developed a flask that permitted storage and transportation of LN thereby rendering LN accessible to physicians.

In 1899, Archibald Campbell White reported on the successful treatment of multiple benign and malignant skin conditions with liquefied air applied via an adapted bottle; the latter could be considered the prototype of modern hand-held units. Herman V. Allington then described how LN-saturated cotton swabs could be used to treat various skin conditions. In 1961, the neurosurgeon Irving S. Cooper, together with Arnold Lee, developed the first cryosurgical probe. Increased use of LN for medical purposes followed the design of safe portable hand-held units.

PRINCIPLES OF CRYOSURGERY AND CRYOBIOLOGY

Cryosurgery is defined as a surgical procedure that utilizes very low temperatures to destroy living tissue. The term *cryotherapy* should be reserved for when living tissue is exposed to cold in order to induce physiological changes but not tissue destruction. *Cryobiology* represents the study of the effects of low temperatures on living tissues.

Heat transfers from hot to cold[2], and the larger the temperature difference between a cryogen and its target tissue, the faster the heat transfer. The ideal cryogen has the lowest possible temperature and is capable of producing the parameters necessary to destroy both benign and malignant cells; for the latter, the tissue temperature needs to be below −50°C. The most commonly used cryogen is LN which boils at −196°C (77°K; −321°F). LN is relatively safe to handle, non-toxic, and commercially available. For the treatment of actinic keratoses (AKs) and cutaneous carcinomas, LN is the recommended cryogen whereas for benign lesions, cryogens with higher boiling points (e.g. liquid nitrous oxide [−88°C], carbon dioxide gas [−78°C], other compressed organic gases [−55 to −75°C]) can also be employed.

The mechanisms of injury in cryosurgery can be attributed to both direct and indirect effects (Table 138.1). Such events are the result of fast freezing followed by slow thawing, i.e. a freeze–thaw cycle. Repeated freeze–thaw cycles increase the destructive effects of cryosurgery. The material interposed between the cryogen and the lesion to be treated is also a determinant of the speed of freezing. *Air* is a poor conductor of cold such that the greater the distance between the skin lesion and the source of the cryogen, the lesser the freezing. *Water* is a better conductor than air (e.g. a presoaked verruca freezes faster), and *ice* is better than water as in the intra- and extracellular ice crystals present after the first freeze–thaw cycle. Finally, *metal* is an excellent conductor explaining the deep and fast freezing of tissue that results from frozen metal probes placed in direct contact with the skin[3].

Different cells and tissues have different sensitivities to cold. The lethal temperature for melanocytes is around −4°C, while that for keratinocytes is −35°C. Keratinocyte cancer cells require around −50°C, sarcoma cells −60°C, and vascular endothelium −15°C to −40°C. Of note, cartilage and bone are quite resistant to freezing.

Cryoimmunology

Cryoimmunology is the study of the innate and humoral immune responses to antigens derived from frozen skin lesions. Development of newer immunologic assays has made it possible to measure such responses, which can be either immunostimulatory or immunosuppressive[4].

One major difference between conventional excisional surgery and cryosurgery is that the latter leaves the tumor "*in situ*". At the center of the frozen lesion, there will be necrosis due to direct cellular damage (see Table 138.1), leading to release of tumor-specific antigens capable of stimulating an immune response. Once the innate immune system is activated, antigen-presenting cells (APCs) engulf tumor fragments and present processed antigens to T cells, initiating both T and B cell immune responses (see Ch. 4). At the periphery, the temperatures are higher and therefore sublethal, with the cells undergoing apoptosis rather than necrosis. This leads to "silent cell death" associated with minimal inflammation (see Table 138.1)[4].

The response to cryosurgery can be enhanced by the addition of adjuvants[5]. These include agents that augment ice injury (e.g. glycine), inducers of apoptosis (e.g. topical 5-fluorouracil)[6], and immunomodulators (e.g. topical imiquimod). Such combinations have been termed *immunocryosurgery*, with promising results having been published[7]. However, further studies are needed to better understand the underlying mechanisms of cryoimmunology, define the ideal parameters for tumor destruction, and determine the precise interactions between cryosurgery and potential adjuvants.

INSTRUMENTS AND TECHNIQUES

Cryosurgical techniques can be subdivided into several types (Table 138.2):

- ***Open*** (***spray***, ***open-spray***; Fig. 138.1A). This is the most frequently used technique. The instrument consists of a metal container with spraying tips or openings through which the cryogen is released. This technique is suitable for lesions that are flat or elevated as well as benign or malignant; the key factor is achieving the correct freezing temperature. Larger openings deliver more LN and freeze tissue faster, so they are ideal for larger, bulky lesions. Smaller openings freeze tissue slower and allow for a more precise freezing. Therefore, they are ideal for small benign lesions, such as lentigines or seborrheic keratoses.

Downloaded for Anonymous User (n/a) at Egyptian Knowledge Bank from ClinicalKey.com by Elsevier on March 10, 2024. For personal use only. No other uses without permission. Copyright ©2024. Elsevier Inc. All rights reserved.

CRYOSURGERY – MECHANISMS OF INJURY				
Type of injury	**Type of cell death**	**Phase**	**Location**	**Type of response**
Direct injury	Necrosis: direct freezing of water leads to extracellular then intracellular ice crystal formation with edema and cellular lysis Temperature required: –20°C for most cells –50°C or lower for malignant cells	Freeze period	Center of treated lesion	Inflammation: +++ Short-lived, nonspecific innate immune response
Vascular injury	Ischemia due to secondary damage of vascular endothelium	Thawing(~1 hour after freezing)	Periphery of treated lesion and normal surrounding skin	Inflammation: +/++
Apoptosis	Occurs at sublethal temperatures, e.g. approx. –20°C for malignant cells	4–8 hours after thawing	Periphery of treated lesion	Inflammation: –/+
Immunologic	Antigens released from damaged cells lead to immune response	Late event	Lymph nodes	Adaptive immune response

Table 138.1 Cryosurgery – mechanisms of injury.

CRYOSURGICAL TECHNIQUES						
Technique		**Common uses**			**Advantages**	**Disadvantages**
Type	**Synonym**	**B**	**PM**	**M**		
Open	Spray Open-spray	√	√	√	Any size or surface	For small lesions, care should be taken regarding normal surrounding skin Not appropriate for pedunculated lesions
Semi-open	Confined spray Cone Confined	√			Relative sparing of normal surrounding skin	Appropriate size of cone required
Semi-closed	Chamber			√	Deep and fast freezing	Indicated for cutaneous malignanciesAppropriate size of chamber required
Closed	Contact Probe Cryoprobe	√		√	Deep and fast freezing	Appropriate size and shape of probe required
Tweezers	Cryotweezers	√			Spares normal surrounding skin Pedunculated lesions	Limited to superficial lesions
Intralesional	–	√		√	Freezing occurs from the center of the lesion	Invasive
Dipstick	Cotton-tipped applicator	√			May be less frightening for children	Variability in amount of LN within cotton tip Loss of temperature control Dripping of LN may lead to unintended sites of freezing

Table 138.2 Cryosurgical techniques. B, benign lesions; LN, liquid nitrogen; M, malignant lesions; PM, premalignant lesions.

- ***Semi-open*** (***confined spray***, ***cone***, ***confined***; Fig. 138.1B). This refers to the use of a polycarbonate plate with holes, neoprene cones, or otoscope specula to restrict sprayed LN to a limited area. All of these items are composed of non-conducting materials. Freezing is faster than with the open technique as the LN is confined to the lesion. As splattering of LN is avoided and normal surrounding tissue is spared, it tends to be less painful.
- ***Semi-closed*** (***chamber***; Fig. 138.1C). One end of a metal cone is attached to the cryogen unit while the rubber-protected distal end is held firmly against the skin. This system generates potent and deep freezing and should be reserved for skin cancers and cutaneous metastases.
- ***Closed*** (***probe***, ***contact***, ***cryoprobe***; Fig. 138.1D,E). The cryogen is delivered via a closed system, i.e. from the unit through metal probes in contact with the skin; the remaining cryogen exits by way of a rubber releasing hose. Probes come in different shapes and diameters. To ensure homogeneous freezing, they need to be applied to flat tumor surfaces. In addition, when treating hemangiomas, the probe should be applied with pressure in order to "press out" the blood and lower the final temperature. For delicate procedures, such as freezing cysts near the eye, ultrasound gel or water can be placed on the skin under the probe.
- ***Tweezers*** (Fig. 138.1F). A previously frozen Teflon® forceps is used to grasp pedunculated lesions. The freezing front is then allowed to advance just to the skin surface. This is an ideal technique for filiform lesions, with sparing of normal surrounding skin as well as minimization of post-treatment hypo- or hyperpigmentation.
- ***Intralesional*** (Fig. 138.1G). While originally developed for keloids, this technique consists of passing a thick needle through the tumor. One end of the needle is attached to the cryogen unit (screwed on or via a Luer lock), while the other end that has exited the skin allows for LN release. It can be used for large nodular tumors where freezing originating from the center of the mass provides an advantage. It is ideal for preserving surrounding tissue.
- ***Dipstick*** (Fig. 138.1H). A LN-saturated, cotton-tipped applicator is placed directly onto the lesion. This technique is still used by some physicians for verrucae and solar lentigines.

PREOPERATIVE CONSIDERATIONS

Patients need to be aware of the relative advantages and disadvantages of cryosurgery compared to other therapies (Table 138.3). A disadvantage is the longer healing times (e.g. ~2–3 weeks for the trunk and arms, >1 month for the legs) while an advantage is the lack of preoperative requirements such that cryosurgery can be performed at the time of the initial office visit. In addition, the need for postoperative

Downloaded for Anonymous User (n/a) at Egyptian Knowledge Bank from ClinicalKey.com by Elsevier on March 10, 2024. For personal use only. No other uses without permission. Copyright ©2024. Elsevier Inc. All rights reserved.

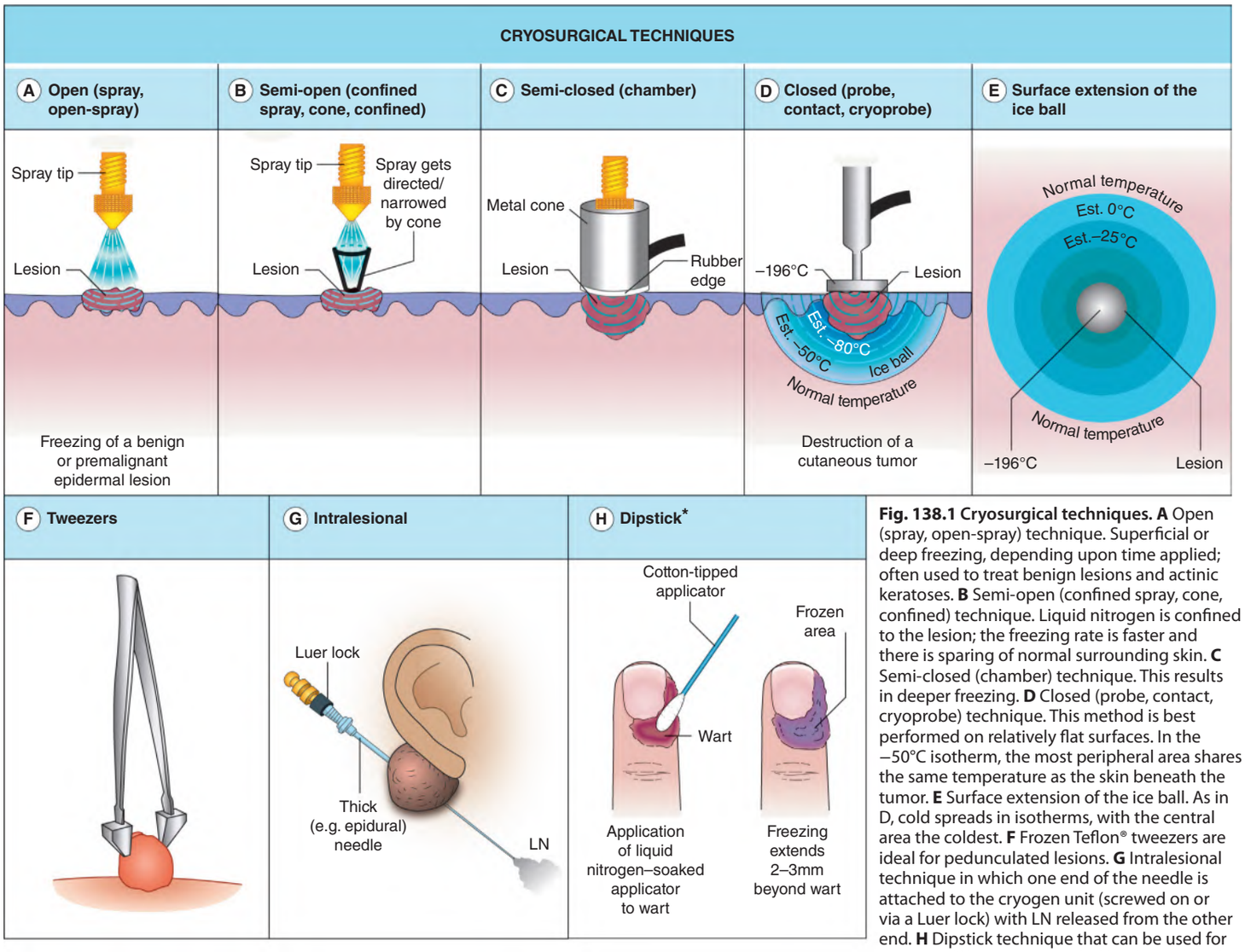

Fig. 138.1 Cryosurgical techniques. A Open (spray, open-spray) technique. Superficial or deep freezing, depending upon time applied; often used to treat benign lesions and actinic keratoses. **B** Semi-open (confined spray, cone, confined) technique. Liquid nitrogen is confined to the lesion; the freezing rate is faster and there is sparing of normal surrounding skin. **C** Semi-closed (chamber) technique. This results in deeper freezing. **D** Closed (probe, contact, cryoprobe) technique. This method is best performed on relatively flat surfaces. In the −50°C isotherm, the most peripheral area shares the same temperature as the skin beneath the tumor. **E** Surface extension of the ice ball. As in D, cold spreads in isotherms, with the central area the coldest. **F** Frozen Teflon® tweezers are ideal for pedunculated lesions. **G** Intralesional technique in which one end of the needle is attached to the cryogen unit (screwed on or via a Luer lock) with LN released from the other end. **H** Dipstick technique that can be used for verrucae. *Not recommended by the author due to the disadvantages listed in Table 138.2.

CRYOSURGERY – ADVANTAGES AND DISADVANTAGES	
Advantages	**Disadvantages**
• Safe and relatively simple procedure • Quick, low-cost procedure • Low-cost equipment (compared to other surgical modalities) • Can be done in the outpatient setting and in nursing homes • Versatility – treatment of a variety of conditions • Treatment of any area of the body, including earlobes, eyelids, nasal alae • Ideal for patients with multiple lesions, allergies to local anesthetics, fear of undergoing surgery, or significant surgical risk due to comorbidities • Minimal, if any, work or sports restrictions • Safe during pregnancy • Excellent cosmetic results	• Longer healing time with deep freezing procedures as second intention healing is required • Contraindicated in patients with cold-triggered conditions or cold-sensitive patients • Hypo- or hyperpigmentation, especially in darker skin phototypes • At free margins, scarring can lead to retraction (e.g. ectropion) • Possible alopecia following deep freezing of hair-bearing areas • Caution required when treating sites with underlying superficial nerves • Not recommended for convex areas, e.g. cheeks • In patients with rosacea, disappearance of erythema at treatment sites can lead to a Swiss cheese-like appearance

Table 138.3 Cryosurgery – advantages and disadvantages. See Table 138.8 for additional details.

care and potential side effects should be reviewed. Contraindications include cold urticaria, cold intolerance, cryoglobulinemia, and other cold-triggered conditions.

For certain clinical situations, skin preparation can improve the effectiveness of cryosurgery. Examples include: (1) removal of excess keratin (a poor conductor of cold) from verrucae via curettage, paring, or application of salicylic or lactic acid for 10–15 days prior to cryosurgery; (2) application of imiquimod to condylomata acuminata; and (3) pretreatment with topical 5-fluorouracil cream[8], diclofenac sodium gel[9], ingenol mebutate gel[10], imiquimod, or retinoic acid cream or gel[11] to remove atrophic and mildly keratotic AKs, with the remaining hyperkeratotic AKs then treated with cryosurgery.

Cryoanesthesia

Cryogens applied for just a few seconds can be used as an anesthetic, e.g. prior to needle insertion or incision and drainage of an inflamed epidermoid cyst. This technique is helpful in needle-phobic patients and can also be used prior to removal of benign lesions (Fig. 138.2)[12].

TREATMENT

Cryosurgery should not be performed without first establishing the correct diagnosis via clinical examination, dermoscopy, and/or histologic examination. The appropriate technique is then chosen (see Table 138.2).

Downloaded for Anonymous User (n/a) at Egyptian Knowledge Bank from ClinicalKey.com by Elsevier on March 10, 2024. For personal use only. No other uses without permission. Copyright ©2024. Elsevier Inc. All rights reserved.

Benign Lesions

Table 138.4 outlines benign conditions that are amenable to cryosurgical management[13]. For some, such as verrucae, it is a first-line option. The open (spray) technique is used for most benign lesions, including verrucae and acne cysts, while the semi-open technique or cryotweezers may be preferred for filiform warts and acrochordons (Video 138.1). The closed (contact, probe) technique can be employed for small adnexal cysts, pseudocysts (e.g. mucoceles), and sebaceous hyperplasia[14] as well as for vascular lesions (e.g. hemangiomas, spider telangiectasias, pyogenic granulomas) (Fig. 138.3). A single freeze–thaw cycle is usually sufficient for benign lesions and cryogens other than LN can be used (see above). Whenever using the spray technique, the use of small diameter apertures and intermittent spraying leads to a more delicate spray and less damage to normal surrounding skin.

For verrucae, removal of excess keratin and moistening of the lesion can improve the effectiveness of cryosurgery (see above). When removing verrucae and seborrheic keratoses, the freezing front should extend a few millimeters beyond the clinical margin to avoid a doughnut wart or residual lesion. If the closed or contact technique is used to treat hemangiomas and other vascular lesions, it is best to prefreeze the probe to prevent it from sticking to the skin surface and to press firmly (see Fig. 138.3). These recommendations are reflected in the PPPP rule: probe • pressure • prefreezing • patience. If the probe does become frozen to the skin lesion, simply allow for thawing before removing the probe. This approach is also recommended for mucosal lesions. Mucoceles may be drained prior to treatment with the closed technique.

Lentigines are lightened with a brief 3- to 4-second freeze and either the open spray or the dipstick technique can be employed. For keloids, the open spray technique – either alone or immediately prior to corticosteroid injection – or the intralesional technique is preferred. In darker skin phototypes, the anticipated cryosurgical technique may initially be performed in a test site that is in a cosmetically insensitive ("hidden") location. The site is then examined for hypo- or hyperpigmentation prior to cryosurgery in other locations.

Premalignant Lesions, Including Actinic Keratoses

Cryosurgery is a very effective therapeutic option for AKs and other premalignant conditions (Fig. 138.4)[15,16]. One 20- to 40-second freeze–thaw cycle is usually sufficient for a 1 cm lesion. The surface temperature reaches −15° to −20°C and, once frozen, the lesion can be grasped between two fingers (Fig. 138.5). Initial freezing should be in the center of the AK, with the freezing front then spreading laterally ~2–3 mm

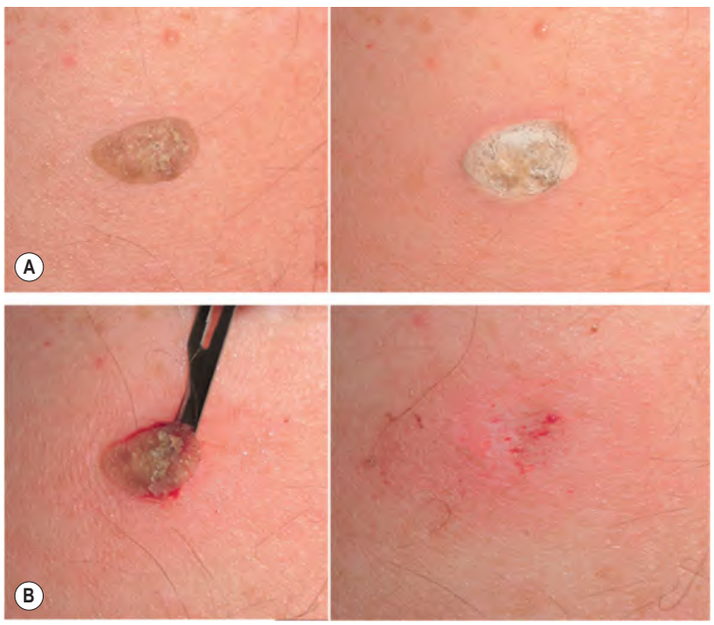

Fig. 138.2 Shave removal of a seborrheic keratosis following the use of liquid nitrogen as an anesthetic. A A seborrheic keratosis (SK) is frozen with a 2–3 mm margin. **B** Once the tissue starts thawing, a swift stroke with a curette or scalpel will make the SK "pop out". A hemostatic solution (aluminum chloride) is applied before complete thawing.

BENIGN CONDITIONS AMENABLE TO CRYOSURGERY	
• Acne cysts	• Lentigo
• Acne keloidalis nuchae	• Lichen sclerosus (of vulva)
• Acne vulgaris	• Lymphangioma
• Acquired perforating disorder	• Cutaneous lymphoid hyperplasia (lymphocytoma cutis)
• Acrochordons	• Molluscum contagiosum
• Angiofibroma	• Mucocele
• Angiokeratomas, including of Fordyce	• Myxoid cyst
• Cherry angioma	• Nevoid hyperkeratosis of the nipple
• Chondrodermatitis nodularis helicis	• Orf
• Chromoblastomycosis	• Pearly penile papules
• Clear cell acanthoma	• Porokeratosis
• Condyloma acuminatum	• Prurigo nodularis
• Dermatofibroma	• Pyogenic granuloma
• Discoid lupus erythematosus	• Rhinophyma
• Eccrine poroma	• Rosacea
• Elastosis perforans serpiginosa	• Sarcoidosis
• Epidermal nevus	• Sebaceous hyperplasia
• Erosive adenomatosis of the nipple	• Seborrheic keratosis
• Folliculitis keloidalis	• Syringocystadenoma papilliferum
• Granuloma annulare	• Syringoma
• Granuloma faciale	• Trichiasis
• Hemangioma	• Trichoepithelioma
• Herpes simplex	• Venous lake
• Keloid	• Verruca vulgaris
• Leishmaniasis	• Xanthoma

Table 138.4 List of benign lesions reported to be amenable to cryosurgical treatment. *Courtesy Emanuel G. Kuflik, MD.*

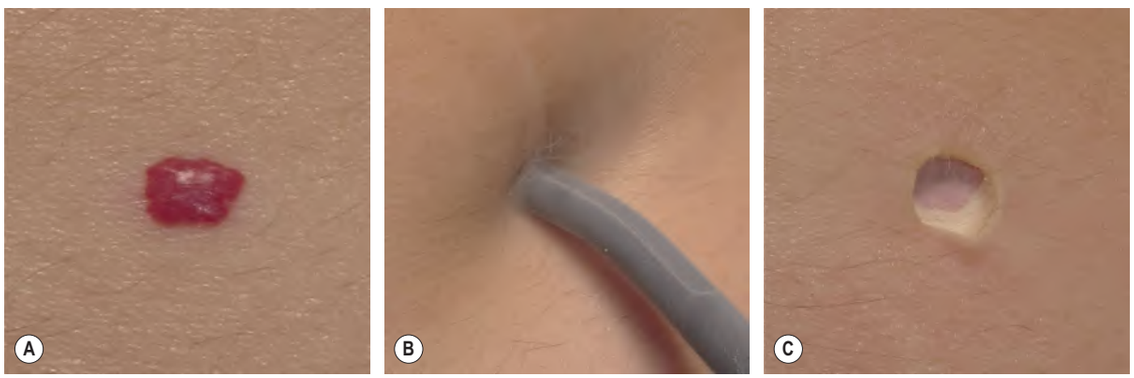

Fig. 138.3 Removal of a cherry angioma via the closed (probe, contact, cryoprobe) technique. A Prior to treatment. **B** A previously frozen probe is pressed into the lesion. **C** The frozen angioma and a transient depression can be seen.

Downloaded for Anonymous User (n/a) at Egyptian Knowledge Bank from ClinicalKey.com by Elsevier on March 10, 2024. For personal use only. No other uses without permission. Copyright ©2024. Elsevier Inc. All rights reserved.

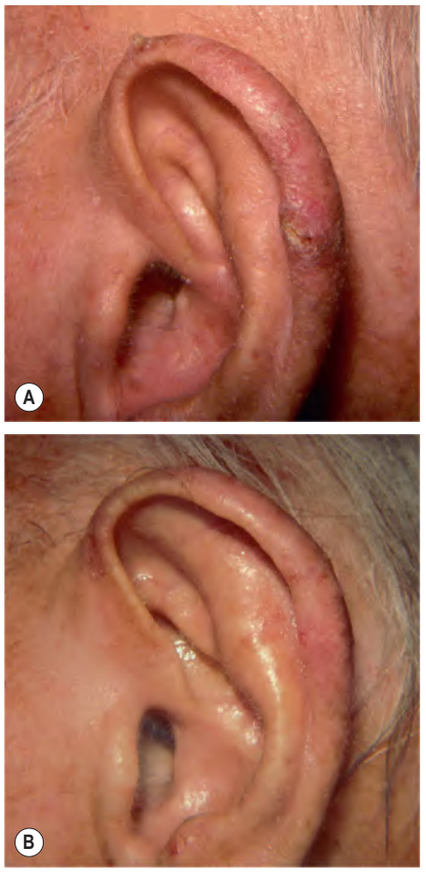

Fig. 138.4 Actinic keratosis treated with the open-spray technique. A Prior to treatment. **B** Three weeks later. *Courtesy Emanuel G. Kuflik, MD.*

Fig. 138.5 Cryosurgery of a hypertrophic actinic keratosis. A Prior to treatment. **B** The open-spray technique should produce a block of frozen tissue that can be grabbed with both fingers; the surface temperature is approximately −15°C.

beyond the clinical margin. Some clinicians treat each lesion with two 15-sec freeze–thaw cycles. Recurrences should be assessed to determine if a squamous cell carcinoma needs to be excluded.

Within areas of significant cutaneous photodamage, there are rarely single AKs but rather multiple AKs as well as subclinical epidermal dysplasia. This is often referred to as "field cancerization" and is best treated by a combination of cryosurgery plus a topical agent (e.g. 5-fluorouracil, imiquimod) or photodynamic therapy. The latter are used to treat subclinical disease and thin lesions while cryosurgery is used to treat thicker keratotic AKs. It is more logical to first treat the field and then use cryosurgery for residual lesions[17].

Cryopeeling refers to the treatment of large areas of photodamaged skin, i.e. field treatment via cryosurgery. The areas of involvement are superficially frozen for 5–10 seconds, and given the associated pain, it is best to apply a topical anesthetic before and immediately after the procedure (see Ch. 143). Individual thicker lesions can be treated at the same time with a longer freeze time (see above)[18]. The freeze time for actinic cheilitis ranges from 10 to 20 seconds.

Cutaneous Malignancies

Cryosurgery is a reasonable alternative for the treatment of skin cancer (Table 138.5), but the lesions and techniques need to be carefully selected[19,20]. Because a double freeze–thaw cycle is more destructive, it is the recommended cryosurgical procedure for skin cancer. Except for very small lesions, local anesthesia is administered. In addition, since keratin is a poor conductor of cold, removal of excess keratin via curettage or paring will assist in reaching the correct freezing temperature at the base of the tumor, thus improving effectiveness[21].

The most commonly used techniques are open (spray) and closed (contact, probe); the closed technique is preferred as it leads to deeper and faster freezing (see Table 138.2). However, it is important to use a probe that corresponds to the size and shape of the tumor to assure complete apposition. The presence of air pockets ("interphase") between the probe and the tumor surface can prevent achievement of the desired final temperature. If the open (spray) technique is chosen, the freezing

CUTANEOUS MALIGNANCIES AMENABLE TO CRYOSURGERY		
Type	**Cryosurgery**	
	Amenable	**Not recommended**
Bowen disease, keratoacanthoma	All	–
Basal cell carcinoma	Especially useful for superficial lesions Tumors with well-defined borders	Morpheaform, infiltrative, and/or recurrent tumors Tumors with ill-defined margins or perineural invasion
Squamous cell carcinoma	Especially useful for superficial lesions Tumors with well-defined borders	Poorly differentiated, infiltrative, and/or recurrent tumors Tumors with ill-defined margins or perineural invasion
Lentigo maligna	Selected cases (e.g. elderly, mutilating surgery required)	
Kaposi sarcoma	Selected lesions that have not responded to other therapies	Avoid plantar surface
Melanoma	As palliation	

Table 138.5 Cutaneous malignancies amenable to cryosurgery.

Downloaded for Anonymous User (n/a) at Egyptian Knowledge Bank from ClinicalKey.com by Elsevier on March 10, 2024. For personal use only. No other uses without permission. Copyright ©2024. Elsevier Inc. All rights reserved.

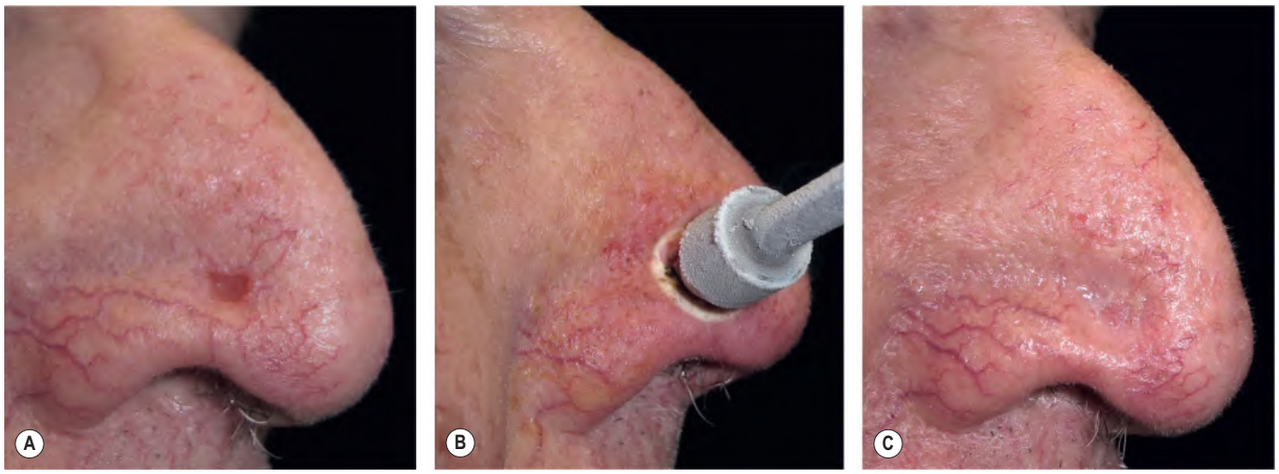

Fig. 138.6 Treatment of a basal cell carcinoma on the nose with the closed (probe, contact, cryoprobe) technique. A Prior to treatment. **B** An appropriately sized frozen cryoprobe is pressed against the tumor; a double freeze–thaw cycle is performed. **C** Healing is nearly complete a few weeks later.

should begin in the center of the tumor followed by lateral spread of the freeze front to 5 mm beyond the clinical margin of the tumor. A similar margin should be obtained with the closed technique.

Because cold advances as isotherms (see Fig. 138.1D,E), temperatures should be measured at the external margin. The temperature can be monitored by measuring (via an infrared thermometer) the surface temperature at the external margin and thereby inferring the temperature at the base of the tumor. More recently, high frequency ultrasound (HFUS; ~22 MHz) has been employed to determine the width, depth, and shape of tumors, thereby providing very useful information for selecting the optimal cryosurgical technique. For example, when basal cell carcinomas (BCCs) are thin, they can be safely treated with either the spray or the probe technique whereas for deeper nodular BCCs, the probe technique is preferred (Fig. 138.6; Video 138.2).

HFUS can also be used to monitor the freezing procedure. An initial black area is seen when the tumor is completely frozen. Re-appearance of the tumor is indicative of thawing, which first occurs at its surface and is last seen at the tumor base. By combining this information with measurement of the temperature[22] at the outer edge of the frozen tumor, the temperature at the base of the tumor can be implied[23].

For patients with multiple BCCs, dermoscopic diagnosis and HFUS of each lesion can be followed by a double freeze–thaw cycle, all in one treatment session. BCCs in several sites, including the nose, ears[24], and eyelids, have been treated successfully with cryosurgery[25]. Immunocryosurgery, consisting of a 5-week course of topical imiquimod with a double freeze–thaw cycle at week two, has also been utilized for skin cancer (Fig. 138.7). Lastly, melanocytes are known to be very sensitive to cold and cryosurgery is an option for selected cases of lentigo maligna (Fig. 138.8)[26,27]. However, it is important to ensure that melanocytes within the follicular epithelium are destroyed. Of note, cryosurgery has also been used, in combination with imiquimod, as treatment for locoregional cutaneous metastases of melanoma[28].

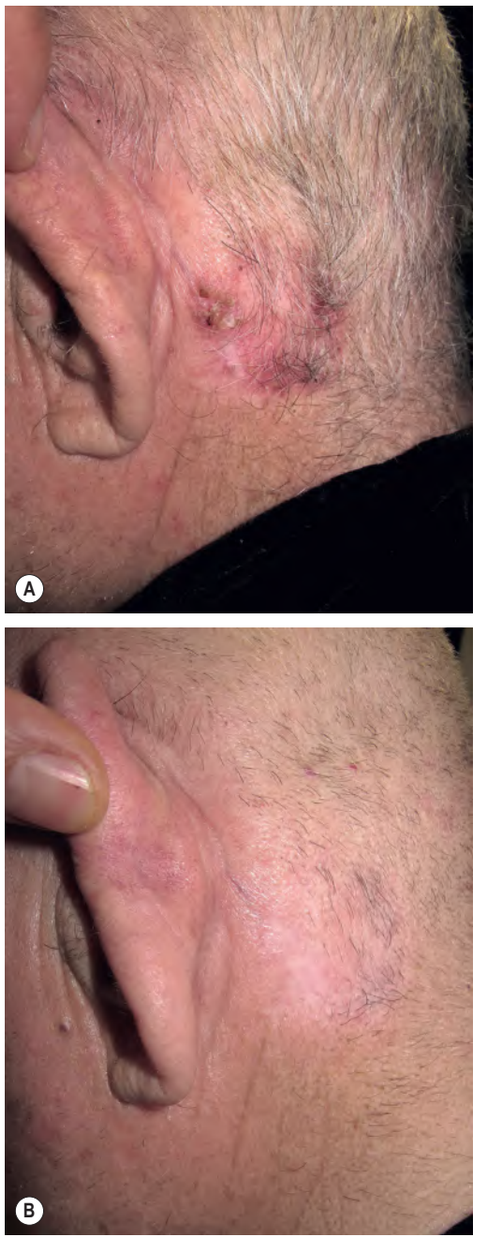

Fig. 138.7 Treatment of a large, ill-defined, postauricular basal cell carcinoma with immunocryosurgery. A Prior to treatment. **B** Eight months later, following a 5-week course of topical imiquimod with a double freeze–thaw cycle at week two.

Palliative Treatment

Cryosurgery has long been used for palliative (compassionate) treatment of skin cancer (Table 138.6)[29]. Detailed discussion with the patient and/or family/caretakers should be undertaken before instituting palliative treatment. The goal is to reduce pain, bleeding, infection, tissue destruction, foul smell, and/or tumoral masses that cause personal and social rejection. Palliative cryosurgery can improve quality of life in individuals with inoperable tumors or in those who reject conventional therapies or are poor surgical candidates due to underlying medical conditions.

Large tumoral masses can be treated by either: (1) the segmental technique; or (2) the fractional technique. In the *segmental* technique, the tumor is divided by imaginary lines into portions. Each segment is treated independently, allowing the freezing fronts to overlap. The aim is to avoid excessive freezing in the center of the tumor prior to the freeze front reaching the periphery. In the *fractional* technique, the center of the tumor is treated and then allowed to heal[30]. As the central

Downloaded for Anonymous User (n/a) at Egyptian Knowledge Bank from ClinicalKey.com by Elsevier on March 10, 2024. For personal use only. No other uses without permission. Copyright ©2024. Elsevier Inc. All rights reserved.

Fig. 138.8 A lentigo maligna on the forehead of a 72-year-old man. A The lesion measures 3.1 × 2.5 cm. **B** Cryosurgery to the entire lesion. Note the wide lateral spread of freeze. **C** The healed cryosurgical site 5 months after treatment. *Courtesy Emanuel G. Kuflik, MD.*

INDICATIONS FOR PALLIATIVE CRYOSURGERY
• Medical comorbidities that lead to significant surgical risk (e.g. cardiac, pulmonary, coagulopathy) • Bedridden patients • Failure of other treatment options • Patient has declined other treatment modalities, e.g. due to possibly disfiguring surgery, transportation issues for radiotherapy • The procedure improves the patient's quality of life or the caregiver's management, e.g. reducing pain, foul smell, bleeding • Mental illness that makes other procedures difficult to accomplish

Table 138.6 Indications for palliative cryosurgery.

scar contracts, it reduces the tumor diameter and residual disease can then be treated. In some patients, repeated treatment of the central tumor is performed to further reduce tumor burden.

The open (spray) technique is most commonly employed, especially in tumors with an irregular surface or in patients with a bleeding diathesis in whom curettage should be avoided. The closed (probe) technique, although ideal for skin cancer treatment, requires probes whose size appropriately matches that of the tumor, and since these tumors are usually very large, proper probes can be difficult to obtain. The semi-closed (chamber) technique, which is very destructive, is ideal for cutaneous metastases as long as the tumor fits inside the chamber. For very large tumors, the intralesional technique is an option.

EXPECTED POSTOPERATIVE EVENTS AND CARE

Compared to conventional excisional surgery, cryosurgery can be performed more rapidly but since healing is by second intention, healing time is prolonged. The latter is especially true for the lower extremities. The expected course and postoperative care are outlined in Table 138.7. Degree of edema will be determined by the depth of the freeze as well as the anatomic location, e.g. cryosurgery of eyelid lesions often leads to more edema (even with light freezing) than does a deep freeze on the arm. Patients with cold sensitivity can also develop more edema after cryosurgery.

For lesions that develop a large bulla, the fluid is often drained to decrease pressure and possibly hasten healing; the blister roof is usually left intact to serve as a biologic dressing although the recommendation of some cryosurgeons is to remove it, especially for verrucae to minimize risk of reimplantation. A gauze dressing can be placed if there is significant oozing and application of a bland topical ointment such as petrolatum enhances second intention healing. Eschars due to cryonecrosis, a later event when deep freezing is performed, should be debrided to facilitate healing.

CRYOSURGERY – POSTOPERATIVE CARE AND EXPECTED SIDE EFFECTS			
Expected side effect	**Time of appearance**	**Duration**	**Postoperative care/Treatment**
Exudation	Hours to days post procedure	Depends on depth of freezing	Wash with soap and water For deep freezing procedures, a bland ointment such as petrolatum can be applied
Pain	During the procedure and a few seconds afterwards (during thawing)	Short-lived	Usually well tolerated In sensitive patients or with deep freezing procedures, use local anesthesia
Urticarial reaction	Immediate	Minutes	None
Edema	A few minutes (sensitive areas) to 12–24 hours post procedure	Depending on the depth and site, a few days to a week Longer duration on the face	No treatment is effective
Vesicle/bulla	Minutes to 24 hours post procedure	Days	Fluid allowed to drain spontaneously or drained by the patient or surgeon
Eschar formation	After a week	Days or weeks	Can be debrided with scissors Care should be taken in vascular lesions

Table 138.7 Cryosurgery – postoperative care and expected side effects.

COMPLICATIONS

As with any surgical procedure, there is the possibility of complications. It is important to distinguish between a severe expected event and a complication, a distinction that is not always obvious. For example, treatment of a tumor in the periorbital region can lead to substantial edema such that the eyelids are swollen shut for several days, and while annoying, this would not be considered a complication. Table 138.8 outlines some of the possible complications of cryosurgery and helpful interventions.

FUTURE TRENDS (IMAGING TECHNOLOGY FOR MONITORING CRYOSURGICAL OUTCOME)

Cryosurgery is now, and will be in the future, a readily available, simple, and cost-effective surgical procedure. As the number of cutaneous

Downloaded for Anonymous User (n/a) at Egyptian Knowledge Bank from ClinicalKey.com by Elsevier on March 10, 2024. For personal use only. No other uses without permission. Copyright ©2024. Elsevier Inc. All rights reserved.

COMPLICATIONS OF CRYOSURGERY	
Complication	**Treatment**
Inadvertent freeze of patient or medical personnel from LN released from vent	Usually none (superficial injury)
LN insufflation (when spray freezing a previously curetted lesion)	None (reabsorbs spontaneously)
Bleeding after removal of eschar that was protecting an underlying vessel	Hemostasis, from simple pressure to electrocoagulation and rarely ligation of bleeding vessel
Pain (after a few days or weeks)	Topical, or occasionally oral, antibiotics if due to infection (most common cause)
Hypo- or hyperpigmentation	If secondary to superficial freezing, it usually improves spontaneously over time With deep freezing procedures, hypopigmentation can be permanent and treatment-resistant
Pseudoepitheliomatous hyperplasia	No treatment required as it resolves over time
Milia	Extraction (occasionally occurs with deep freezing procedures)
Scar retraction/notching	Permanent as due to tissue destruction from the tumor and its treatment; reconstructive surgery is an option
Alopecia	Can be permanent following deep freezing procedures in hair-bearing sites
Atrophic/depressed scar	Usually improves with time, but is sometimes permanent, especially following deep freezing procedures

Table 138.8 Complications of cryosurgery. LN, liquid nitrogen.

malignancies increases worldwide with many amenable to minimally invasive techniques, principles and proper techniques become an essential component of the scope of practice of dermatology and should be familiar to all dermatologists. Cryosurgery will clearly benefit from the newer non-invasive imaging techniques (e.g. dermoscopy, HFUS, confocal microscopy[31], optical coherence tomography[32]) that assist in diagnosis and provide information on the depth, volume, and histology of cutaneous tumors. In addition, these techniques can improve margin control while the effects of freezing can be visualized *in situ*. Non-invasive devices that measure skin temperature should also provide valuable information that can be used to standardize cryosurgical procedures.

Additional figures available in our eBook (see inside front cover for access code).

REFERENCES

1. Cooper SM, Dawber RP. The history of cryosurgery. *J R Soc Med*. 2001;94:196–201.
2. Stańczyk M, Telega JJ. Thermal problems in biomechanics–a review. Part III. Cryosurgery, cryopreservation and cryotherapy. *Acta Bioeng Biomech*. 2003;5:3–22.
3. Gage AA, Baust JM, Baust JG. Experimental cryosurgery investigations in vivo. *Cryobiology*. 2009;59:229–243.
4. Sabel MS. Cryo-immunology: a review of the literature and proposed mechanisms for stimulatory versus suppressive immune responses. *Cryobiology*. 2009;58:1–11.
5. Goel R, Anderson K, Slaton J, et al. Adjuvant approaches to enhance cryosurgery. *J Biomech Eng*. 2009;131:074003.
6. Clarke DM, Baust JM, Van Buskirk RG, Baust JG. Chemo-cryo combination therapy: an adjunctive model for the treatment of prostate cancer. *Cryobiology*. 2001;42:274–285.
7. Gaitanis G, Bassukas ID. Immunocryosurgery for non-superficial basal cell carcinoma: a prospective, open-label phase III study for tumours ≤2 cm in diameter. *Acta Derm Venereol*. 2014;94:38–44.
8. Jorizzo J, Weiss J, Furst K, et al. Effect of a 1-week treatment with 0.5% topical fluorouracil on occurrence of actinic keratosis after cryosurgery: a randomized, vehicle-controlled clinical trial. *Arch Dermatol*. 2004;140:813–816.
9. Mastrolonardo M. Topical diclofenac 3% gel plus cryotherapy for treatment of multiple and recurrent actinic keratoses. *Clin Exp Dermatol*. 2009;34:33–35.
10. Berman B, Goldenberg G, Hanke CW, et al. Efficacy and safety of ingenol mebutate 0.015% gel after cryosurgery of actinic keratosis: 12-month results. *J Drugs Dermatol*. 2014;13:741–747.
11. Ianhez M, Fleury Jr LF, Miot HA, Bagatin E. Retinoids for prevention and treatment of actinic keratosis. *An Bras Dermatol*. 2013;88:585–593.
12. Pasquali P, Freites-Martinez A, Fortuño-Mar A. Cryobiopsy: an alternative technique to conventional shave biopsy. *J Am Acad Dermatol*. 2015;73:867–868.
13. Andrews MD. Cryosurgery for common skin conditions. *Am Fam Physician*. 2004;69:2365–2372.
14. Ataş H, Gönül M. Evaluation of the efficacy of cryosurgery in patients with sebaceous hyperplasia of the face. *J Cutan Med Surg*. 2017;21:202–206.
15. Ianhez M, Miot HA, Bagatin E. Liquid nitrogen for the treatment of actinic keratosis: a longitudinal assessment. *Br J Dermatol*. 2014;170:1114–1121.
16. Zane C, Facchinetti E, Rossi MT, et al. Cryotherapy is preferable to ablative CO2 laser for the treatment of isolated actinic keratoses of the face and scalp: a randomized clinical trial. *Br J Dermatol*. 2014;170:1114–1121.
17. Pasquali P, Segurado-Miravalles G, Baldi A, et al. Monitoring sequential treatment of actinic keratosis using post-processed images: ingenol mebutate and cryosurgery. *Photodermatol Photoimmunol Photomed*. 2019;35:447–448.
18. Chiarello SE. Cryopeeling (extensive cryosurgery) for treatment of actinic keratoses: an update and comparison. *Dermatol Surg*. 2000;26:728–732.
19. Kuflik EG. Cryosurgery for skin cancer: 30-year experience and cure rates. *Dermatol Surg*. 2004;30:297–300.
20. Bernardeau K, Derancourt C, Cambie M, et al. Cryosurgery of basal cell carcinoma: a study of 358 patients. *Ann Dermatol Venereol*. 2000;127:175–179.
21. Samain A, Boullié MC, Duval-Modeste AB, Joly P. Cryosurgery and curettage-cryosurgery for basal cell carcinomas of the mid-face. *J Eur Acad Dermatol Venereol*. 2015;29:1291–1296.
22. Goldberg LH, Kaplan B, Vergilis-Kalner I, Landau J. Liquid nitrogen: temperature control in the treatment of actinic keratosis. *Dermatol Surg*. 2010;36:1956–1961.
23. Pasquali P. High-frequency ultrasound (HFUS) in the management of skin cancer treated with cryosurgery. In: Pasquali P, ed. *Cryosurgery. A Practical Manual*. Berlin: Springer-Verlag; 2015:159–171.
24. Nordin P, Stenquist B. Five-year results of curettage-cryosurgery for 100 consecutive auricular non-melanoma skin cancers. *J Laryngol Otol*. 2002;116:893–898.
25. Lindgren G, Larkö O. Cryosurgery of eyelid basal cell carcinomas including 781 cases treated over 30 years. *Acta Ophthalmol*. 2014;92:787–792.
26. McLeod M, Choudhary S, Giannakakis G, Nouri K. Surgical treatments for lentigo maligna: a review. *Dermatol Surg*. 2011;37:1210–1228.
27. Bassukas ID, Gamvroulia C, Zioga A, et al. Cryosurgery during topical imiquimod: a successful combination modality for lentigo maligna. *Int J Dermatol*. 2008;47:519–521.
28. Rivas-Tolosa N, Ortiz-Brugués A, Toledo-Pastrana T, et al. Local cryosurgery and imiquimod: a successful combination for the treatment of locoregional cutaneous metastasis of melanoma: a case series. *J Dermatol*. 2016;43:553–556.
29. Kuflik EG. Cryosurgery for palliation. *J Dermatol Surg Oncol*. 1985;11:867–869.
30. Gonçalves JC. Fractional cryosurgery for skin cancer. *Dermatol Surg*. 2009;35:1788–1796.
31. Pasquali P, Segurado-Miravalles G, Freites-Martínez A, et al. Cryosurgical management of basal cell carcinoma: in vivo follow-up using reflectance confocal microscopy. *Int J Dermatol*. 2019;58:e30–e32.
32. Themstrup L, Banzhaf C, Mogensen M, Jemec GB. Cryosurgery treatment of actinic keratoses monitored by optical coherence tomography: a pilot study. *Dermatology*. 2012;225:242–247.

Downloaded for Anonymous User (n/a) at Egyptian Knowledge Bank from ClinicalKey.com by Elsevier on March 10, 2024. For personal use only. No other uses without permission. Copyright ©2024. Elsevier Inc. All rights reserved.

eFig. 138.1 Shave removal of a cutaneous horn following use of liquid nitrogen as an anesthetic. A Cutaneous horn of the lower eyelid. **B** Brief superficial freeze (5–7 seconds). **C** Shave removal with a scalpel. **D** Aluminum chloride solution (hemostatic agent) was applied prior to the onset of bleeding. No pain was felt by the patient.

eFig. 138.2 Squamous cell carcinoma on the cheek of an 83-year-old disabled woman. A The lesion measured 6×4.5 cm. **B** Prior to cryosurgery, the tumor was shaved flush with the surrounding skin in order to assure proper probe apposition. **C** Two years post cryosurgery, there is a hypopigmented scar without evidence of tumor recurrence.

Downloaded for Anonymous User (n/a) at Egyptian Knowledge Bank from ClinicalKey.com by Elsevier on March 10, 2024. For personal use only. No other uses without permission. Copyright ©2024. Elsevier Inc. All rights reserved.

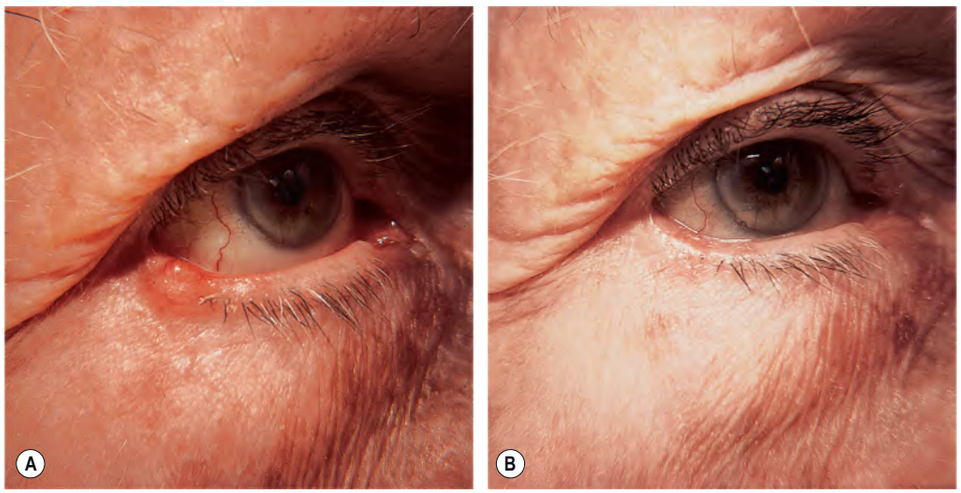

eFig. 138.3 Basal cell carcinoma on the right lower eyelid margin. A Papular lesion with telangiectasias on the eyelid margin of an 82-year-old woman. **B** The healed cryosurgical site 6 months after treatment. Excellent cosmetic result; note loss of cilia. *Courtesy Emanuel G. Kuflik, MD.*

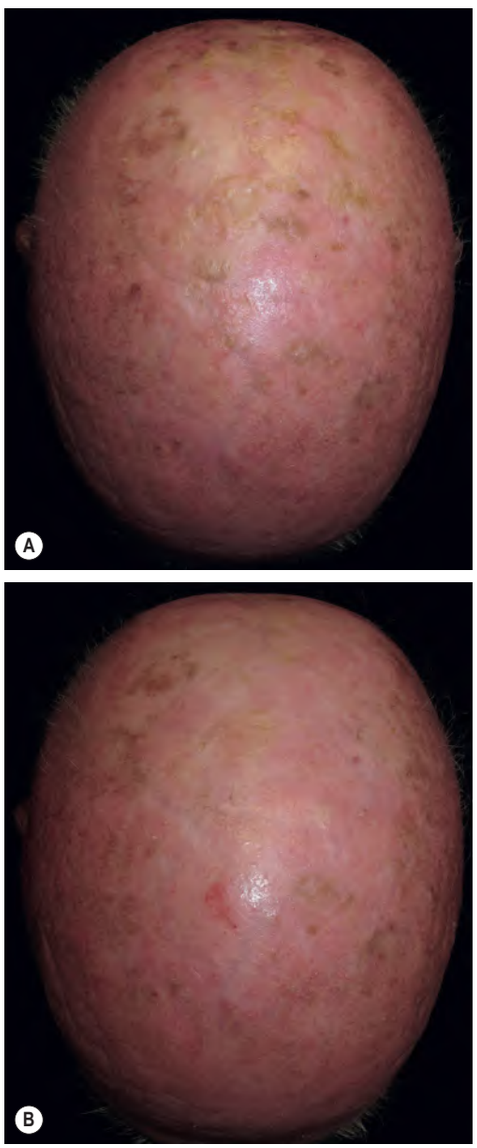

eFig. 138.4 Cryopeeling. Liquid nitrogen is sprayed for a few seconds onto the entire area of photodamaged skin utilizing an acne aperture; the latter is an aperture that emits a soft, vaporized spray. Topical anesthesia is applied one hour before and immediately after freezing the skin. **A** Prior to treatment. **B** After a single treatment.

Downloaded for Anonymous User (n/a) at Egyptian Knowledge Bank from ClinicalKey.com by Elsevier on March 10, 2024. For personal use only. No other uses without permission. Copyright ©2024. Elsevier Inc. All rights reserved.